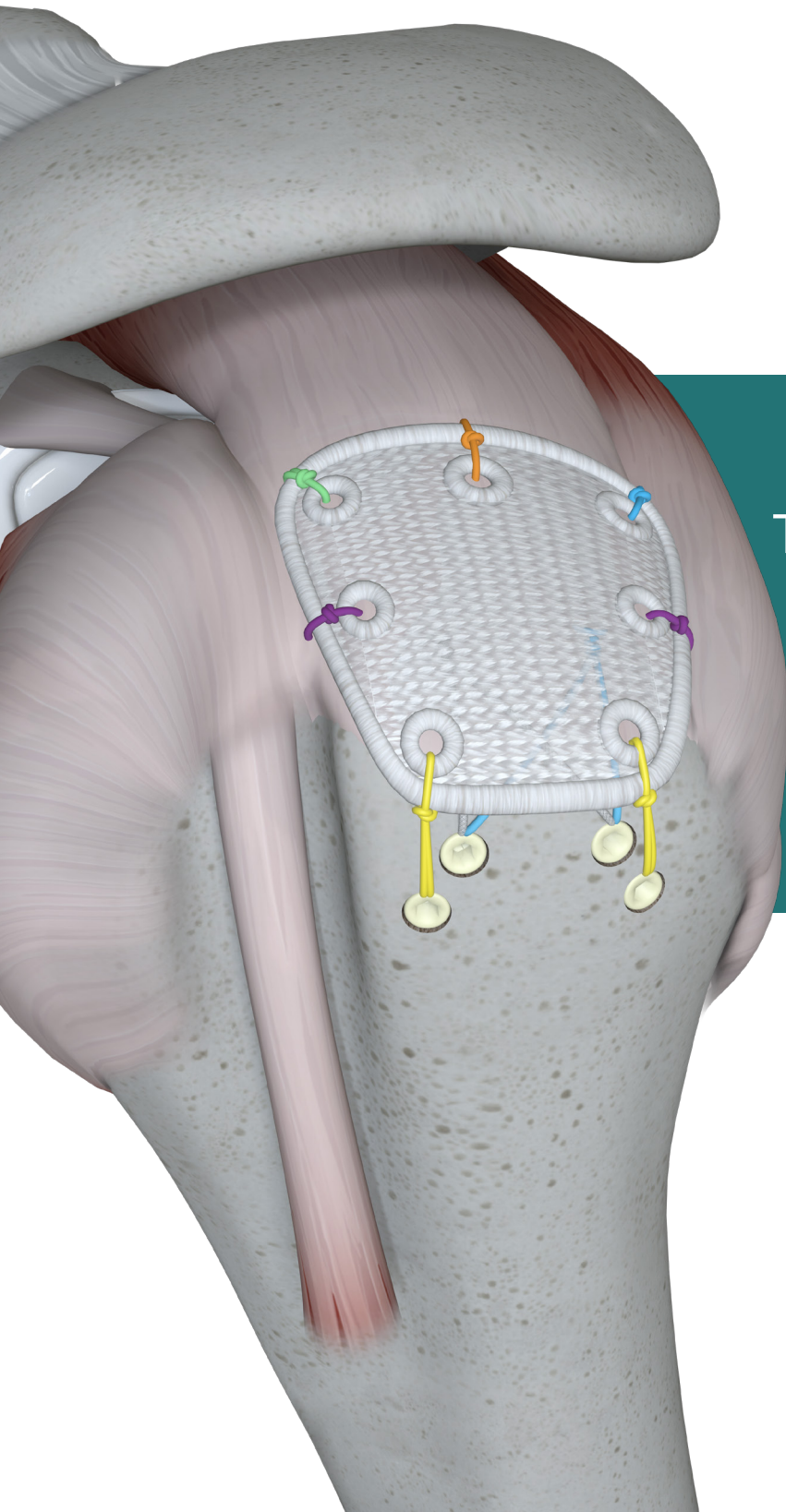

Pitch-Patch

Tissue reinforcement for
rotator cuff repair
Arthroscopic technique

Surgical Technique Manual

Pitch-Patch Arthroscopic technique

Introduction

The **Pitch-Patch** concept;

- The **Pitch-Patch** is a permanently implantable patch constructed from non-absorbable Polyester (poly (ethylene terephthalate) fibres), for reinforcement of the rotator cuff following or during repair by sutures or suture anchors.
- The **Pitch-Patch** has a warp knitted structure that allows a natural body response whereby native tissue integrates into the device.
- The shape is designed to fit the anatomy.
- It features a reinforced border and incorporates reinforced, prepared holes for the sutures, up to size #5.
- It is available in two sizes to cover different tear sizes of the rotator cuff: 30 mm x 20 mm and 35 mm x 25 mm.
- Polyester implants have a long history of routine use in joint surgery. They are well tolerated and show little foreign body tissue reaction.
- Unlike biological tissue, the polyester material used for the **Pitch-Patch** does not cause any immunological reaction.
- Testing of this special design has shown a very high average strength of over 400 N when fully sutured along the medial edge (3 sutures) for the standard patch. ^[1]
- The **Pitch-Patch** can be applied using an open or arthroscopic technique for the reinforcement of the rotator cuff.
- The **Pitch-Patch** is not intended for stand-alone bridging (replacement of the cuff with insufficient closure).

Indications

- The **Pitch-Patch** is a single-use device intended to be used for reinforcement of the rotator cuff following or during repair by sutures or suture anchors, where weakness exists in the soft tissue.
- The **Pitch-Patch** is indicated for patients requiring reinforcement of the rotator cuff where either the tear cannot be completely repaired using normal methods and/or the quality of the soft tissue is poor.
- The **Pitch-Patch** is not intended to replace normal body structure or provide the full mechanical strength to support the rotator cuff. Sutures, used to repair the tear, and suture or suture anchors, used to attach the tissue to the bone, provide mechanical strength for the repair.
- Further information regarding indications and contraindications are available in the Instructions For Use (IFU) LAB 195.

etzelclinic and the Pitch-Patch story

The **Pitch-Patch** was devised by Dr. Med. Jan Leuzinger of the etzelclinic with first implantations in 2012. As rotator cuff (RC) repair techniques developed; with improved anchors, high strength sutures and effective suture passing devices, RC repair still suffered from reported high re-tear rates. ^[2, 3, 4]

The remaining weak link was the quality of the native tissue available for repair. A number of patch techniques and materials have been devised for the repair of massive RC tears. Dr Leuzinger proposed a poly-ethylene terephthalate (polyester) anatomically shaped and reinforced device, that would offer immediate strength and allow a standardised rehabilitation programme determined by the underlying tissue repair and not modified due to the patch itself.

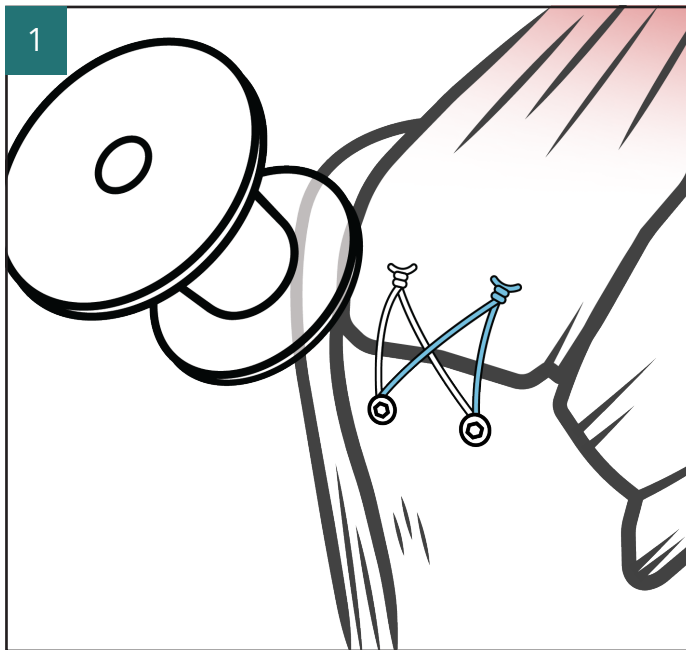
A study published in the JSES in 2019 concluded for the **Pitch-Patch**; "patch augmentation in massive RC reconstruction leads to a substantially lower re-tear rate." ^[5]

Surgical Technique

Surgical Technique Guide

This guide commences from when the underlying repair has been completed by the surgeon's determined method. For illustration purposes, we illustrate a TOE bridge-type repair as the underlying construct. Patient positioning may be either "beach chair" or lateral decubitus as per surgeon preference.

A subacromial decompression may be performed to create sufficient space to manage the repair and **Pitch-Patch** augmentation.



Portals:

Arthroscopic portals previously made for the TOE repair may be used. Additional portals for suture management and passing are made as required. Examples of these are described in the following surgical steps. The portals used and their location should be selected upon access to the tissue to be repaired and the surgeon's own experience.

Image 1: Typically, a cannula of sufficient diameter to deliver the folded **Pitch-Patch** is placed anterolaterally as a working cannula. The developing team commonly utilise a "soft" cannula for this purpose.

Suture passing:

The authors favour a range of suture passers to either pass shuttle sutures or repair sutures directly through the cuff. It is the responsibility of the operating surgeon to select the most appropriate instrument based upon the presenting pathology and the surgeon's own experience.

Anchor selection

Anchor selection as per surgeon experience and preference. The technique developers typically use a knotless self-punching anchor for the lateral fixation of the **Pitch-Patch**.

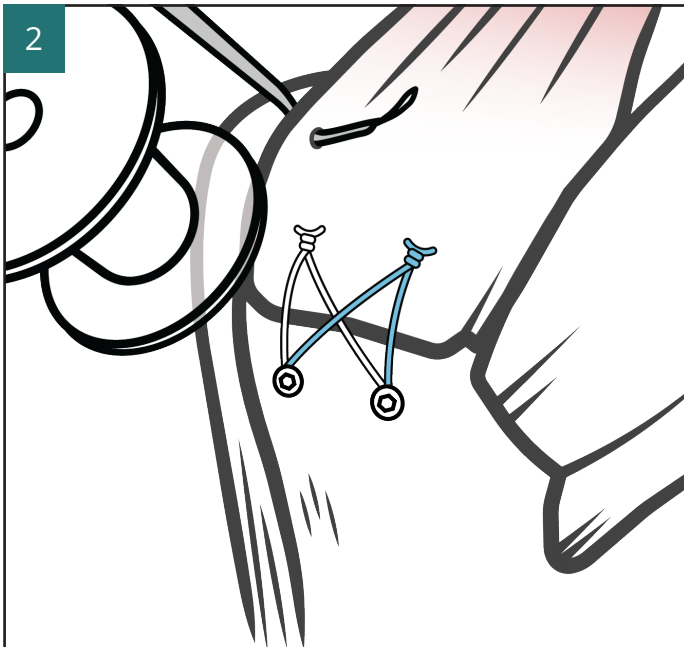
Size selection of the Pitch-Patch:

In most cases the standard size **Pitch-Patch** is found to provide good coverage of the underlying repair and provides secure suture placement through good quality tissue. The large size **Pitch-Patch** is recommended when the tear is larger, and the adjacent tissue is of poorer quality. The large **Pitch-Patch** covers more tissue and provides additional fixation points to create a secure reinforcement.

Pitch-Patch sizes

102-1090XI **Pitch-Patch**, Standard, 30 mm x 20 mm (supplied sterile)

102-1091XI **Pitch-Patch**, Large, 35 mm x 25 mm (supplied sterile)



Introduction of, and medial fixation of the Pitch-Patch; antero and posteromedially

Image 2: Medial suture passing

A needle type suture passing device is used to position a PDS shuttle suture for the anteromedial attachment of the **Pitch-Patch**. This is positioned between the medial mattress sutures of the underlying repair and the musculotendinous junction of the cuff (Supraspinatus).

The PDS suture is used to shuttle a #2 high strength suture through the cuff. Both limbs of the suture are parked through the anterosuperior portal.

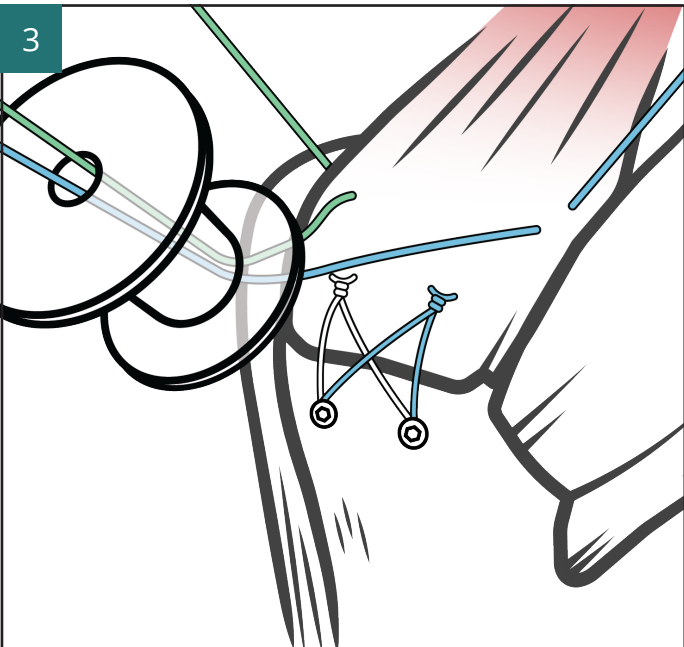


Image 3: Repeated process for the posteromedial attachment of the Pitch-Patch.

A Lasso type passing device is used to position a PDS shuttle suture for the posteromedial attachment of the **Pitch-Patch**. This is positioned between the medial mattress sutures and the musculotendinous junction of the cuff (Supraspinatus).

The PDS suture is used to shuttle a #2 high strength suture through the cuff. Both limbs of the suture are parked through the posterosuperior portal.

Surgical tip:

- Use different coloured #2 high strength sutures to assist with suture management and identification.

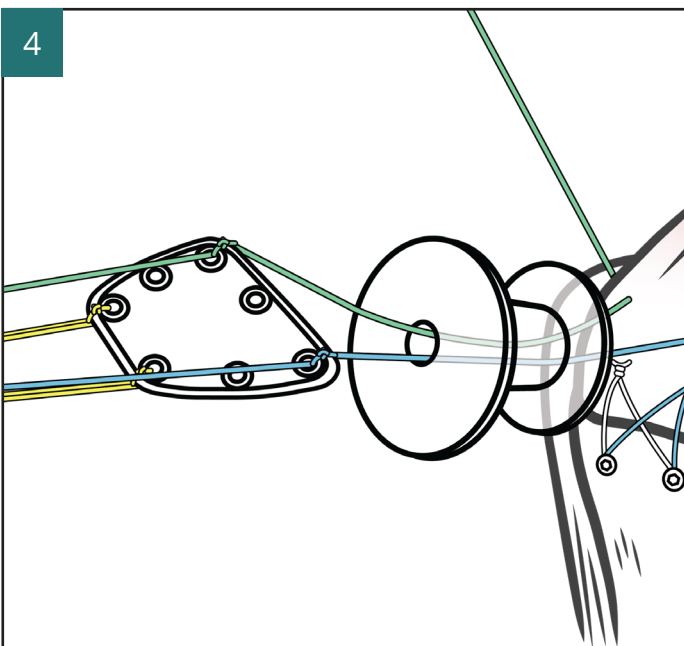


Image 4: Delivering the Pitch-Patch into the shoulder

Retrieve one limb of each suture through the soft cannula.

Surgical tips:

- Adjust both the suture lengths to approximately 2/3 outside the soft cannula and 1/3 outside the parking portals.
 - Ensure the limbs do not twist in the shoulder or as they pass through the soft cannula.
- Outside the shoulder prepare the **Pitch-Patch** by passing the sutures through the corresponding fixation holes AM to AM and PM to PM. Lock each suture to the **Pitch-Patch** with a locking knot.

Place an additional suture through each of the lateral holes and secure with a locking knot.

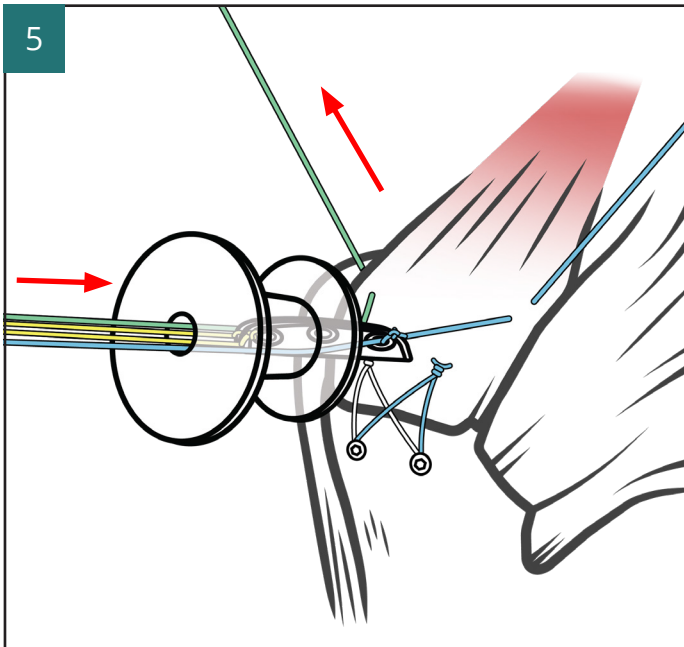
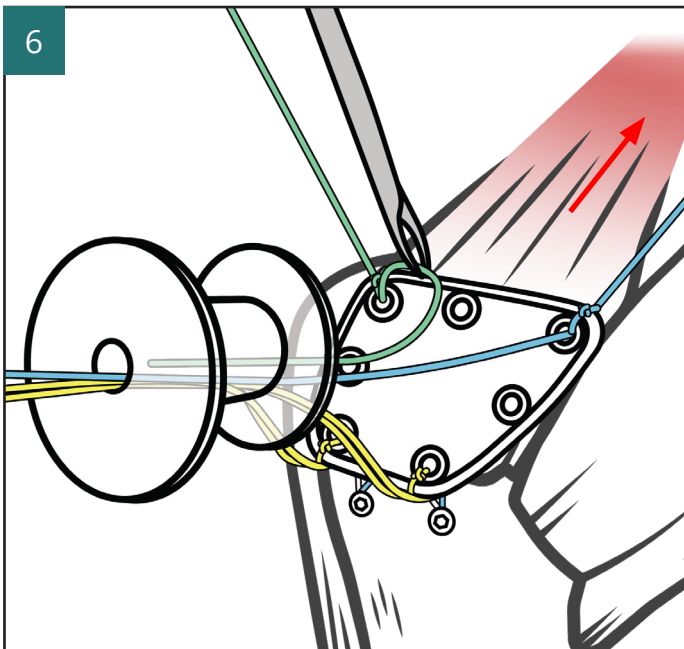


Image 5: The **Pitch-Patch** is folded sides towards the centre to create a “W” shape and carefully introduced into the shoulder through the soft cannula.

A long nose clamp such as a Pean forceps may be used to secure the folded **Pitch-Patch** and deliver through the cannula.

As the **Pitch-Patch** is advanced through the soft cannula, carefully draw the AM and PM sutures to take up suture slack and assist with delivery of the **Pitch-Patch** into the shoulder.

Once the **Pitch-Patch** is in the shoulder, release and withdraw the clamp, the AM and PM sutures are pulled to deploy the **Pitch-Patch** onto the superior surface of the cuff.



A probe or grasper may be used to ensure the **Pitch-Patch** lays flat onto the cuff with no twists.

Image 6: The trailing suture limbs attached to the medial fixation holes of the **Pitch-Patch** are retrieved via their corresponding suture park portals.

Surgical tip:

- To avoid tissue bridges it is recommended to retrieve both the trailing limb and the parked limb simultaneously.

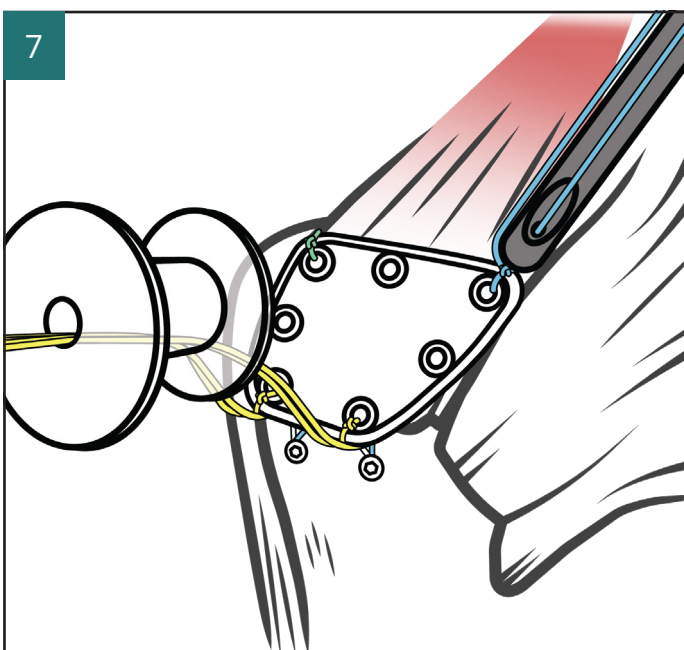


Image 7: Medial knotting and fixation of the Pitch-Patch

The anteromedial suture is tensioned and tied in a locking knot using an arthroscopic knot pusher and then cut to leave a short tail behind the knot.

The posteromedial suture is tensioned and tied in a locking knot using an arthroscopic knot pusher and then cut to leave a short tail behind the knot.

Lateral tensioning and fixation of the Pitch-Patch with self-punching knotless suture anchor

Lateral fixation is typically performed with two additional knotless anchors. Care is taken not to connect with or undermine the previously placed lateral anchors of the TOE /Bridge repair.

Typically, these anchors will be positioned slightly further lateral and offset to the positions of the TOE lateral anchors.

A suture grasping forcep introduced through the soft cannula is used to ensure the **Pitch-Patch** is laying flat over the repaired cuff, and then to retrieve both limbs of the high strength #2 suture attached to the anterolateral fixation hole of the **Pitch-Patch** out via the soft cannula. This ensures that the suture limbs are not twisted with, and are separated from, the posterolateral **Pitch-Patch** suture.

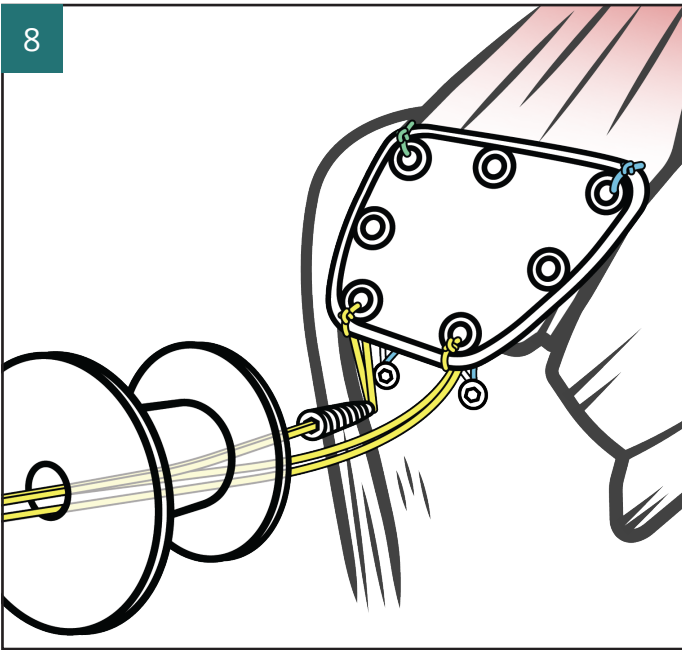


Image 8: Anterolateral anchor fixation of the Pitch-Patch

Pass both limbs of the anterolateral suture through the eyelet of the self-punching knotless anchor. Introduce into the shoulder via the soft cannula and position at the desired lateral fixation point on the humerus for the **Pitch-Patch**. Pull out any slack in the suture and draw the **Pitch-Patch** towards the anchor.

Once the desired tension is achieved, advance the anchor into bone until it is flush with the cortex. Suture tension is confirmed. The anchor introducer is removed, and suture tails are cut.

(Note: The correct suture tensioning technique related to the selected fixation device should be employed. Alternatively, a knotted anchor technique may be used).

The remaining suture limbs passing through the soft cannula are for the posterolateral fixation of the **Pitch-Patch**.

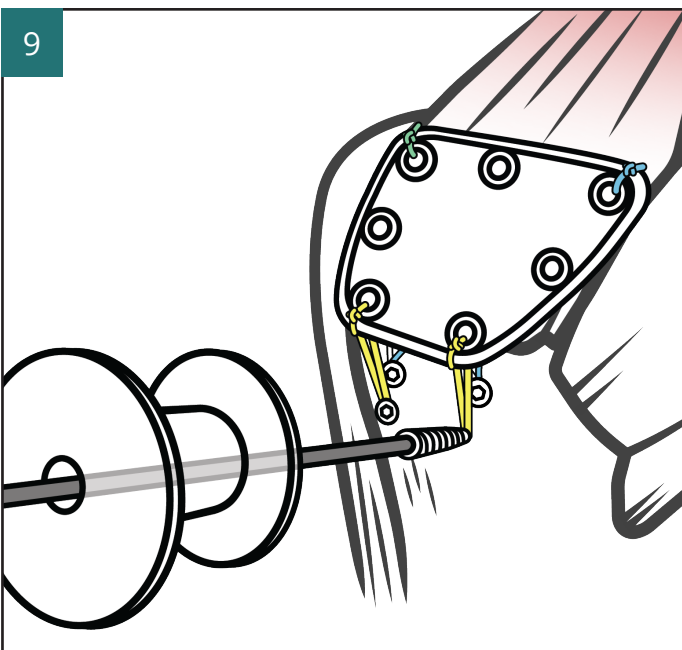


Image 9: Posterolateral anchor fixation of the Pitch-Patch

Repeat of similar steps for the anterolateral fixation.

Pass both limbs of the posterolateral suture through the eyelet of the self-punching knotless anchor.

Introduce into the shoulder via the soft cannula and position at the desired lateral fixation point on the humerus for the **Pitch-Patch**. Pull out any slack in the suture and draw the **Pitch-Patch** towards the anchor.

Once the desired tension is achieved, advance the anchor into bone until it is flush with the cortex. Suture tension is confirmed. The anchor introducer is removed, and suture tails are cut.

(Note: The correct suture tensioning technique related to the selected fixation device should be employed. Alternatively, a knotted anchor technique may be used).

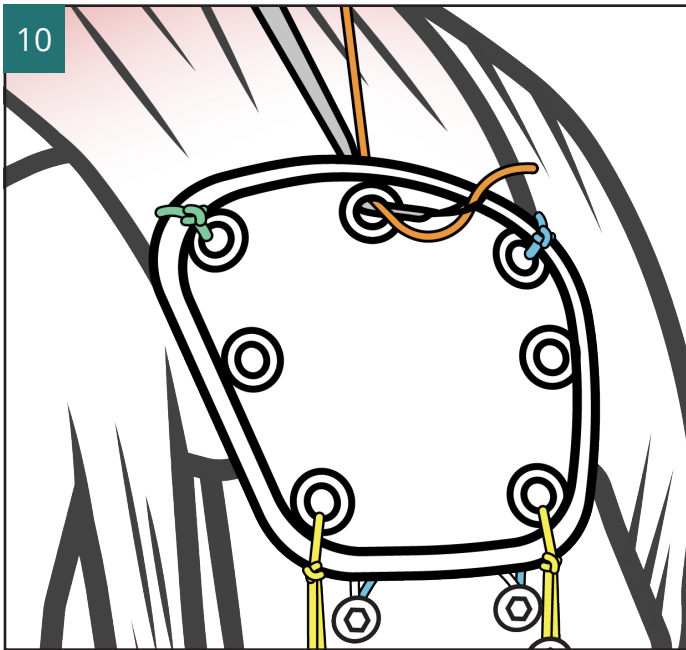


Image 10: Centre medial fixation of the Pitch-Patch

For the Standard size **Pitch-Patch** there is one centre-medial hole for suture attachment of the **Pitch-Patch** to the rotator cuff.

Note: In the case of the large size of **Pitch-Patch** there are two centre medial holes for suture attachment of the **Pitch-Patch** to the rotator cuff. The same described technique is used for both attachments.

A suture needle type passing device may be used to position and pass a suture for the centre-medial attachment of the **Pitch-Patch**.

This suture is used directly to secure the **Pitch-Patch** to the cuff. Both passed limbs are retrieved via the soft cannula. It is tied in a locking knot with a knot pusher and the suture tails are cut.

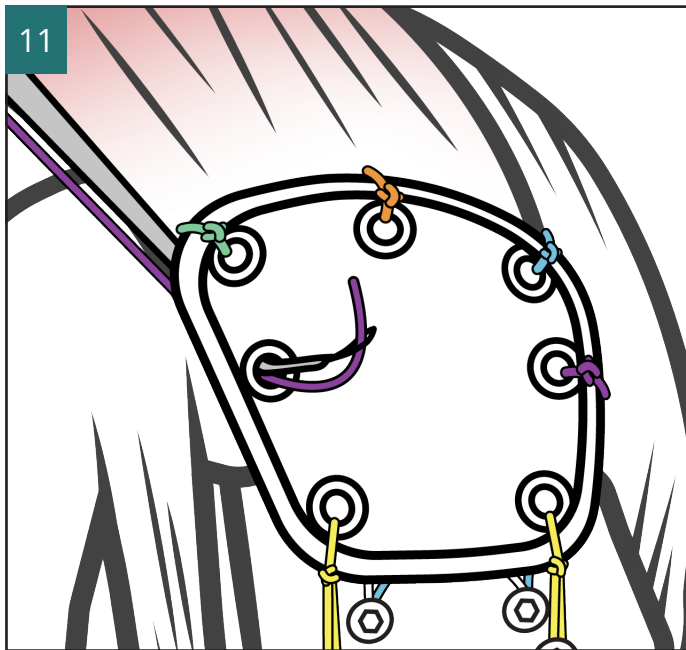


Image 11: Mid-posterior fixation of the Pitch-Patch

A suture needle type passing device is used to position and pass a PDS suture for the mid-posterior attachment of the **Pitch-Patch**.

This suture is used directly to secure the **Pitch-Patch** to the cuff. Both passed limbs are retrieved via the soft cannula. It is tied in a locking knot with a knot pusher and the suture tails are cut.

Mid-anterior fixation of the Pitch-Patch

A suture needle type passing device is used to position and pass a PDS suture for the mid-anterior attachment of the **Pitch-Patch**.

This suture is used directly to secure the **Pitch-Patch** to the cuff. Both passed limbs are retrieved via the soft cannula. It is tied in a locking knot with a knot pusher and the suture tails are cut.

Note: Centre-lateral fixation of the Large Pitch-Patch

Use of this fixation hole is considered optional.

This is used in cases of poorer quality bone stock laterally and the surgeon decides that an additional lateral point of fixation is required.

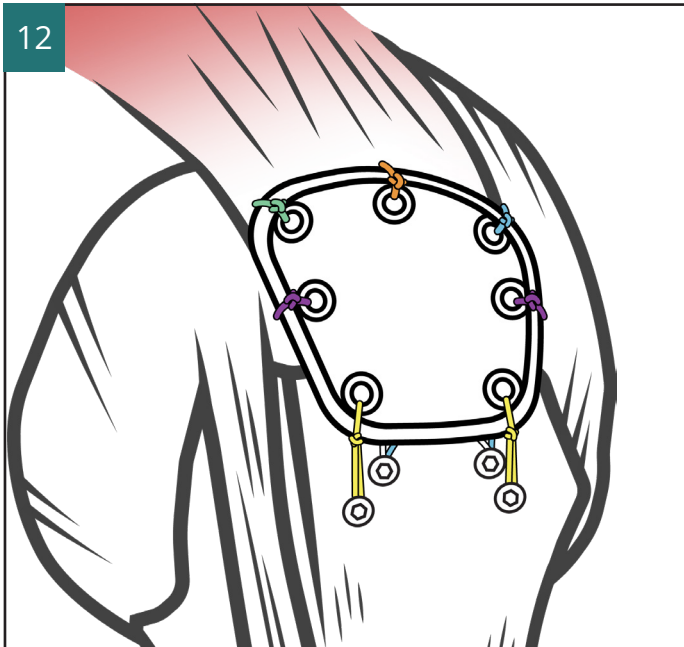


Image 12: Pitch-Patch finished construct
The finished construct is inspected and cannulas are removed.

Wound closure and dressings as per surgeon preference.

Postoperative Management

Postoperative management

Immediate post-operative care

As per standard rotator cuff protocols. The developing surgeons routinely use shoulder sling, +/- abduction cushion to reduce tension in the repair construct. Cryotherapy and pain relief medication including NSAR's as required.

Post-operative rehabilitation programme

The **Pitch-Patch** Rehabilitation Programme (LAB 303) offers further information of the developing surgeon's preferred rehabilitation programme. This programme has been translated and reproduced with the kind permission of the shoulder team at the etzelclinic.

Please go to www.xiros.co.uk for a downloadable version.

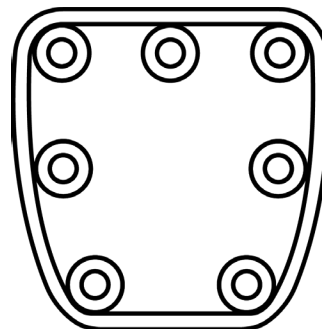
References

1. Xiros. Data on file
2. Chung SW, Kim JY, Kim MH, Kim SH, Oh JH. Arthroscopic Repair of Massive Rotator Cuff Tears: Outcome and Analysis of Factors Associated With Healing Failure or Poor Postoperative Function. *The American Journal of Sports Medicine*. 2013;41(7):1674-1683. doi:10.1177/0363546513485719
3. Kim JR, Cho YS, Ryu KJ, Kim JH. Clinical and radiographic outcomes after arthroscopic repair of massive rotator cuff tears using a suture bridge technique: assessment of repair integrity on magnetic resonance imaging. *Am J Sports Med*. 2012 Apr;40(4):786-93. doi: 10.1177/0363546511434546. Epub 2012 Feb 3. PMID: 22307079.
4. Choi S, Kim MK, Kim GM, Roh YH, Hwang IK, Kang H. Factors associated with clinical and structural outcomes after arthroscopic rotator cuff repair with a suture bridge technique in medium, large, and massive tears. *J Shoulder Elbow Surg*. 2014 Nov;23(11):1675-81. doi: 10.1016/j.jse.2014.02.021. Epub 2014 May 24. PMID: 24862247.
5. Smolen D, Haffner N, Mittermayr R, Hess F, Sternberg C, Leuzinger J. Application of a new polyester patch in arthroscopic massive rotator cuff repair-a prospective cohort study. *J Shoulder Elbow Surg*. 2020 Jan;29(1):e11-e21. doi: 10.1016/j.jse.2019.05.015. Epub 2019 Aug 9. PMID: 31405714.

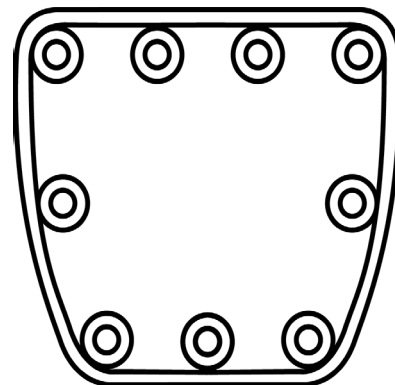
Ordering Information

Implant

102-1090XI **Pitch-Patch**, Standard, 30 mm x 20 mm



102-1091XI **Pitch-Patch**, Large, 35 mm x 25 mm



Xiros products and their indications are subject to regional variations. To confirm availability in your region/country please contact enquiries@xiros.co.uk

Please refer to the Instructions for Use leaflet packed with the **Pitch-Patch** for essential information including Use, Sterility, Indications, Contraindications, Warnings and Precautions, Potential Adverse Effects and Storage. Additional copies may be obtained from the Xiros™ Sales Department, or downloaded from www.xiros.co.uk



Developed and manufactured by

Xiros™ Ltd

Springfield House
Whitehouse Lane
Yeadon
Leeds LS19 7UE
UK

Tel. +44 (0) 113 238 7202
Fax. +44 (0) 113 238 7201
enquiries@xiros.co.uk
www.xiros.co.uk

Xiros Limited, Registered in England No.
1664824.

All rights reserved. © Xiros™ 2023.
Worldwide patents and patents pending.

Xiros is a trademark of Xiros.

This description of technique is provided as an educational tool and clinical aid to assist appropriately licensed Healthcare Professionals in the usage of specific Xiros products. As part of this professional usage, the Healthcare Professional must use their professional judgment in making any final determinations in product usage and technique. In doing so, the Healthcare Professional should rely on their own training and experience and should conduct a thorough review of pertinent medical literature.