



Infinity-Lock™ 5 mm for MCL Repair and Augmentation

Case Report: Darren Johnson, MD, University of Kentucky

Case Introduction

The patient is a 27-year-old male who sustained an injury to his left knee after falling off his dirt bike and landing awkwardly on his leg. Previously patient underwent left knee ACL reconstruction with hamstring autograft 2 years prior to his injury. MRI demonstrated injuries to his ACL graft and tibial-sided avulsion of the MCL. On exam he had a positive Lachman and anterior drawer test as well as opening to valgus stress at 0° & 30° of knee flexion. Below is the technique utilized for the primary repair of the MCL and augmentation with the **Infinity-Lock** suture tape.

Surgical Technique

The **Infinity-Lock** 5 mm tape was doubled over and trimmed to 16 cm (native MCL measures 12 cm) to allow for adequate tensioning of the graft in our tunnels. Both ends were whipstitched with a heavy non-absorbable suture. Diagnostic arthroscopy was performed, and positive drive-through-sign was noted medially with significant lift-off of the meniscus from the tibia (Figure 1). This was stabilized with two all-inside meniscal suture devices.

Curvilinear incision for our repair started centered over the medial epicondyle of the knee proximally and approximately 6 cm distally centered over the anterior and posterior aspects of the tibial shaft. The medial epicondyle and proximal MCL insertion was identified and marked with electrocautery.

Distal MCL avulsion was identified superficial to the pes anserine tendons. Three double-loaded all-suture anchors were placed at the deep MCL insertion 1 cm distal to the joint line. All suture limbs from the anchors were utilized to secure the MCL fibers to this attachment. Next, a transverse incision in the sartorial fascia was made and a heavy suture was used to retract the pes anserine tendons distally to visualize the distal MCL insertion.

The tibial tunnel was reamed (6 mm diameter) to the lateral cortex and subsequently tapped to accommodate our bio-composite interference screw. Passing pin was placed through our tunnel and the limb of our **Infinity-Lock** was passed through our tunnel and interference screw was placed. Previously marked femoral tunnel was drilled (6 mm diameter) to accommodate our interference screw. Tunnel was reamed in a posterior-to-anterior and slightly proximal direction to approximately 30 mm. Passing pin was placed through our tunnel and limb of the **Infinity-Lock** suture was passed through our tunnel. Prior to insertion of our interference screw the **Infinity-Lock** suture was tensioned with the knee in 30° of flexion, neutral rotation, and slight varus force at the ankle.

Once adequately tensioned, the interference screw was placed. The fascia was closed over the pes tendons distally as well as the layers proximally over the medial epicondyle. Suture of the **Infinity-Lock** 5 mm tape to the native MCL using Vicryl suture along the entire construct may be done for reinforcement.

Post-operatively patient was locked at 30° in a TROM brace and made toe-touch weight bearing for 6 weeks.

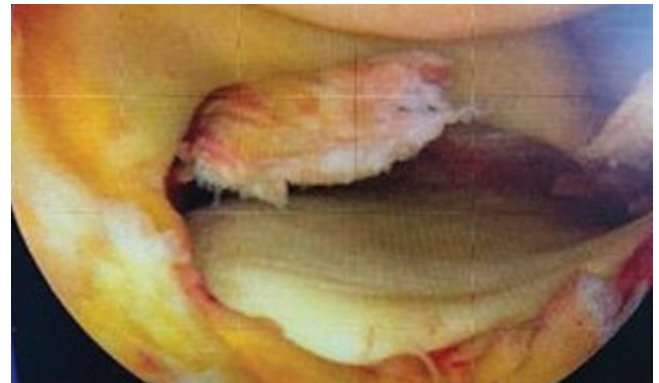

Figure 1 - Arthroscopic medial compartment demonstrating significant tibial sided meniscal lift-off and drive-through sign.

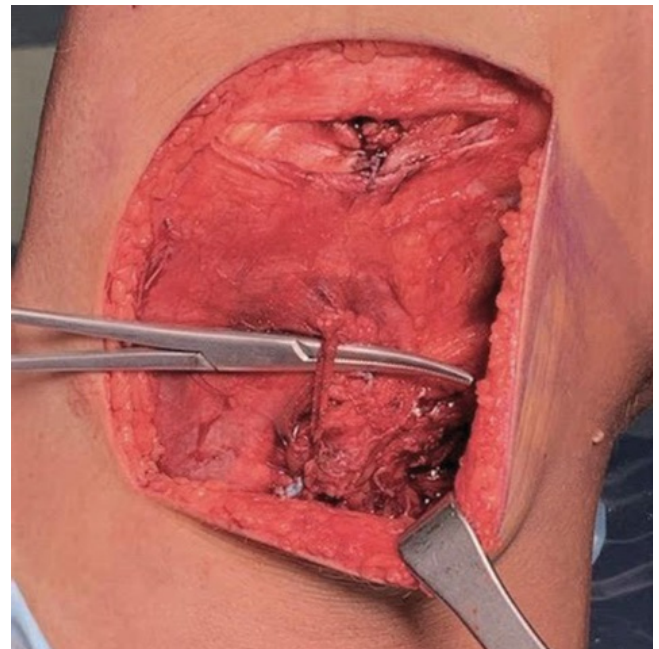


Figure 2 - Final construction showing **Infinity-Lock** tape overlying native LCL



Infinity-Lock™ 5 mm for MCL Repair and Augmentation

Case Report: Darren Johnson, MD, University of Kentucky

Xiros™ Ltd

Springfield House, Whitehouse Lane, Leeds LS19 7UE

T. +44 (0) 113 238 7202

E. enquiries@xiros.co.uk

Xiros Limited, registered in England No. 1664824

All rights reserved. © Xiros™ 2023. Worldwide patents and patents pending.

Xiros and **Infinity-Lock** are trademarks of Xiros.

WP 025 2.00