

Case Introduction

The patient is a 17-year-old male high school football player who sustained an injury to his left knee when another player landed on the lateral aspect of his knee. MRI demonstrated isolated rupture of MCL from its tibial insertion. Physical exam was significant for Grade 3 laxity with valgus stress and no firm endpoint at 30° of knee flexion, and 1+ opening with firm endpoint with valgus at stress at 0°. Patient failed attempt at conservative management. Below is the technique utilized for MCL reconstruction with semi-tendinosis allograft and **Infinity-Lock** 5 mm tape augmentation.

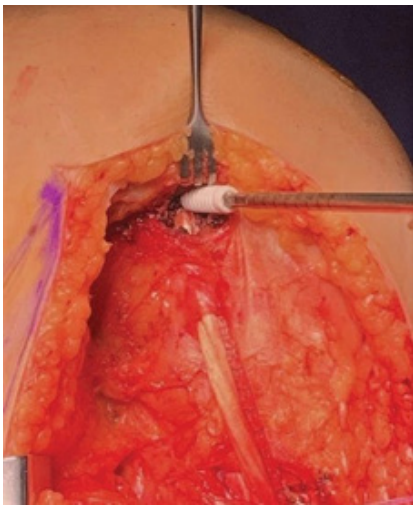


Figure 1 - Proximal femoral tunnel.

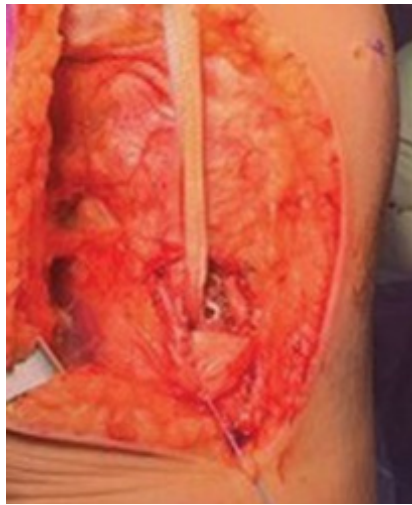


Figure 2 - Distal tibial tunnel with pes tendons retracted distally.

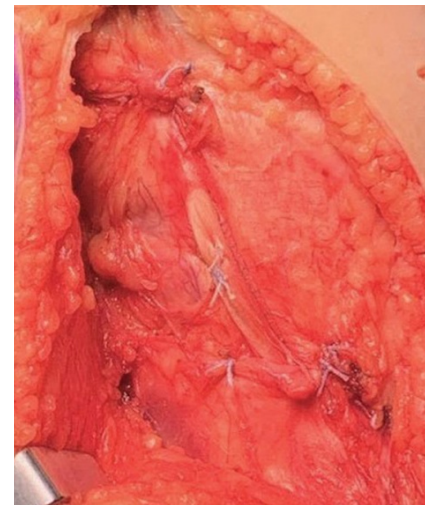


Figure 3 - Final construct with semi-tendinosis allograft superficial to **Infinity-Lock**.

Surgical Technique

Semi-tendinosis allograft tissue was prepared on the back table. Graft was trimmed to 16 cm (native measures 12 cm) to allow for adequate tensioning of the graft in our tunnels. Both ends were whipstitched with a heavy non-absorbable suture. The **Infinity-Lock** 5 mm tape was trimmed to the same length as our allograft and whipstitched in similar fashion. Diagnostic arthroscopy was performed, and approximate 1.5 cm drive-through-sign was noted with significant lift-off of the meniscus from the tibia.

This was stabilized with two all-inside meniscal suture devices. Curvilinear incision for our reconstruction started centered over the medial epicondyle of the knee proximally and approximately 6 cm distally centered over the anterior and posterior aspects of the tibial shaft. The medial epicondyle and adductor tubercle were identified proximally and pes anserine insertion distally.

Proximal insertion of the MCL was located proximal and posterior to the medial picondyle. Electrocautery was utilized to mark the origin of the MCL and proposed tunnel site.

Pes anserine tendons were located approximately 6 cm distal to the joint. The overlying fascia was incised, and a traction stitch was placed in the tendons and fascia to gain access to the insertion deep to the tendons. Tibial tunnel was reamed (6 mm drill) to the lateral cortex and subsequently tapped to accommodate our biocomposite interference screw. Passing pin was placed through our tunnel and of the allograft and **Infinity-Lock** were passed through our tunnel and interference screw was placed. Previously marked femoral tunnel was drilled (6 mm) to accommodate our interference screw. Tunnel was reamed in a posterior-to-anterior and slightly proximal direction to approximately 30 mm.

Passing pin was placed through our tunnel and the proximal allograft and **Infinity-Lock** were passed through our tunnel. Prior to insertion of our interference screw graft and **Infinity-Lock** were tensioned with the knee in 30° of flexion, neutral rotation, and slight varus force.



Infinity-Lock™ 5 mm for MCL Reconstruction and Augmentation

Case Report: Darren Johnson, MD, University of Kentucky

Surgical Technique continued

Once adequately tensioned, the interference screw was placed. A double-loaded all suture anchor was placed 1 cm distal to the joint line and all limbs passed through our allograft and the **Infinity-Lock** tape and subsequently tied to recreate the deep MCL insertion site.

The fascia was closed over the pes tendons distally as well as the layers proximally over the medial epicondyle. Suture of the tape to the allograft using vicryl suture along the entire construct may be done.

Patient was locked at 30° in a TROM brace and made toe-touch weight bearing for 6 weeks.

Xiros™ Ltd

Springfield House, Whitehouse Lane, Leeds LS19 7UE

T. +44 (0) 113 238 7202

E. enquiries@xiros.co.uk

Xiros Limited, registered in England No. 1664824

All rights reserved. © Xiros™ 2023. Worldwide patents and patents pending.

Xiros and **Infinity-Lock** are trademarks of Xiros.

WP 026 2.00